

GFL



German as a foreign language

Brain representations of writing

Rüdiger J. Seitz, Düsseldorf

ISSN 1470 – 9570

Brain representations of writing

Rüdiger J. Seitz, Düsseldorf

Abstract

Functional neuroimaging has been used to map the brain structures involved in the execution and guidance of arm and hand movements during writing, in the learning of writing movements and in relation to the linguistic components of written speech production. It was shown that handwriting, like other visuospatial motor tasks, involves motor and premotor cortical areas as well as dorsal stream areas of sensory processing, including the superior parietal cortex. In addition, ventral stream areas such as the left parieto-temporo-occipital junction were activated in relation to visual word forms as were the left inferior frontal gyrus and left inferior parietal cortex in relation to the production of symbolic characters. The neural correlates of designing a coherent text and elaborating a text by re-iterative modification, however, remain topics for future research.

1. Introduction

Writing is a multilayered process which has been explored using different approaches and research techniques. Functional neuroimaging provides a means of mapping the brain structures activated in relation to a specific task, e.g. writing. By using inferential statistics and stereotactic reference coordinate systems, probabilistic accounts of the brain areas involved in this type of brain work are generated, which has general implications. There is hope of achieving a detailed understanding of the underlying brain processes that cannot be studied in non-human primates, but are specific for humans. There are two major issues that need to be addressed in this context. First, one would like to know what the characteristics of these research tools are, to see the advantages, and to realize their limitations. Second, one needs to analyze the processes underlying writing to understand which aspects have been studied so far or are promising for future studies. These two aspects will be discussed in this article.

2. Functional neuroimaging methods

Functional neuroimaging is a powerful technology for mapping human brain function that was developed in the last decade of the 20th century. Most widely used are measurements of stimulation-related haemodynamic changes. Initially, these changes were assessed with measurements of the regional cerebral blood flow (rCBF) using positron emission tomography (PET), and later with measurements of the blood oxygenation level-dependent changes (BOLD) using functional magnetic resonance imaging (fMRI). These tomographic imaging tools can localize brain activity changes with relatively good spatial resolution of approximately 5 to 9 mm (Frackowiak et al. 1994, Calamante et al. 1999). In comparison to the thickness of the cerebral cortex and the dimensions of the subcortical grey matter structures, however, this is still a limited spatial resolution. Similarly, the temporal resolution of PET and fMRI is also relatively poor, being in the range of approximately 1 s to 1 min, due to the haemodynamic characteristics of the measurements. Nevertheless, the reconstructed tomographic imaging data allow us to detect activity changes occurring simultaneously in different parts of the brain, including the different parts of the cerebral cortex, subcortical structures such as the basal ganglia and thalamus, and the cerebellum. It should be born in mind, however, that the observed haemodynamic changes represent only indirect measures of brain activity. PET-measurements of rCBF function by identifying significant changes that persist in the steady-state during the scanning interval compared to the control steady-state. FMRI exploits the consistency of activation-related changes over a couple of subsequent activation-control cycles (Frahm et al. 1992, Bandettini et al. 1997). Although under physiological conditions there is a tight coupling of activation-related metabolic and haemodynamic changes to increases in neural activity (Fox et al. 1984, Blomqvist et al. 1994, Bandettini et al. 1997, Hoge et al. 1999), bioelectric neural activity has a time-course in the range of several milliseconds, faster than the haemodynamic measures by three orders of magnitude. Therefore, one of the assumptions underlying functional imaging with PET and fMRI is that a state of activation has to be kept constant over a sufficiently long period of time in order to capture functional changes during a condition approaching a steady state. In fact, Logothetis and collaborators (2001) were able to show by simultaneous recordings of fMRI signals and microelectrode recordings in the visual cortex of primates that the time course and spatial location of the stimulation induced BOLD-increase correlated with the time course and spatial location of stimulation induced brain electric activity. Notably, this brain electric activity was the population

response of nerve cell assemblies, e.g. local field potentials, while the discharges of single neurons decayed rapidly, obscuring a correlation of the BOLD-response with single unit activity. Changes of brain activity were originally conceptualized as increased activity in a task-specific stimulation condition, as compared to a specific control condition (Raichle 1987). However, task-specific decreases in brain activity are also of interest (Seitz & Roland 1992a, Drevets et al. 1995, Shulman et al. 1997, Kastrup et al. 2007). Such categorical comparisons were based on the simplified model of psychological subtraction (Petersen et al. 1988, Kosslyn et al. 1995). In addition, in factorial designs, the main effects of each variable, as well as the interaction between these variables in the different psychophysical tasks, can be identified explicitly (Price et al. 1997). Also, biomathematical approaches have been developed to account for coherent brain activity in different brain regions, in relation to defined task conditions (Alexander & Moeller 1994, Friston 1994, McIntosh & Gonzalez-Lima 1994, Büchel et al. 1997). These statistical approaches can be subdivided into those that are hypothesis-driven and region-based, thus restricting the search space by imposing an external model (McIntosh et al. 1994, Büchel et al. 1997, Azari et al. 1999), and those that are data driven and evaluate the functional connectivity in the entire matrix of the image data (Friston et al. 1993, Hartmann et al. 2008). More recently, fMRI has been developed further to accommodate also activity recordings in an event-related fashion (D'Esposito et al. 1997, Buckner et al. 1998, Friston et al. 1998, Beauchamp et al. 1999). These measurements can achieve a high spatial and high temporal resolution (Menon & Kim 1999). The areas that survive the different steps of image analysis are usually converted to pseudocoloured hot spots, which thereafter can be superimposed onto co-registered structural MR images or anatomical templates (Steinmetz et al. 1992a, Frackowiak 1994). These hot spots indicate those areas in the brain that are specifically involved in a given task. However, it is becoming increasingly clear that such an area is not uniquely specialized for one task, but rather may also subserve related cerebral operations.

Since in functional neuroimaging, brain images of different people are to be analyzed for groups of subjects and we want to compare image points that correspond to identical anatomical structures, tools have been developed to morph one individual brain into that of another person or into a common standard. In such a standard, activations can be described in stereotactic coordinates which allows the comparison across different laboratories and studies. Most widely used for this purpose is the stereotactic atlas of Talairach & Tournoux (1988). A major problem

in this process is the inter-individual variability of the human brain. In vivo MRI has shown that gyral configuration of the human brain is highly variable among different individuals and largely determined by epigenetic factors (Steinmetz et al. 1992b, Amunts et al. 1997, Kennedy et al. 1998). Also, there are interhemispheric differences within and between the sexes, probably related to differences in handedness, skills, and capacities (Schlaug et al. 1995, Gur et al. 1999). Approaches to spatial standardization using linear and non-linear transformation procedures are confounded with residual inter-subject variability of several millimeters in magnitude in terms of structural inter-subject variability (Evans et al. 1988, Seitz et al. 1990, Friston et al. 1994, Roland et al. 1997). Conversely, it is well recognized that spatial image standardization may create virtual activation centers by merging of small, closely adjacent activity changes (Worsley et al. 1992). More recently, there are techniques emerging which can transform brains that they match perfectly (Schormann & Kraemer 2002). Nevertheless, there is also considerable inter-subject variability of the cerebral activation patterns that appeared to be related to individual task performance (Schlaug et al. 1994, Hunton et al. 1996, Hasnain et al. 1998). Thus, in the case of a high mean activation signal related to consistent performance across subjects, the individual location of the activation focus is more similar than in case of a low mean signal. In the latter case the low mean signal could be due either to low activity change as well as less consistent performance across subjects.

3. Functional Neuroanatomy

The idea of functional neuroimaging is to develop an atlas which shows the localization of functions in the human brain. Brain science has learnt a lot from lesion studies in patients in that neurological deficits were correlated with brain lesions. Broca (1861) described a patient with an infarct lesion in the left inferior frontal cortex who suffered a deficit of speech production. Only a few years later Wernicke (1874) reported a patient with an infarct lesion in the left parietal cortex who was severely impaired in comprehension of speech. Later, it became clear that lesions in the left inferior frontal cortex can also disrupt writing, as a lesion in the inferior temporo-occipital cortex can selectively impair reading. By careful neurological or neuropsychological analyses and correlation of functional deficits with brain lesions, a differentiated picture of the relevance of the different brain areas for brain functions including language processing has been developed

(Mesulam 1990). However, brain lesions do not necessarily show the spot in the brain where a certain function originates. The brain structures that are important for a certain brain function can only be identified by studying this brain function with neuroimaging methods in healthy people. Moreover, anatomical landmarks such as cerebral sulci do not translate into microanatomical borders within the cerebral cortex, which was demonstrated for the inferior frontal gyrus or Broca's area (Lindenberg et al. 2007). Thus, probabilistic maps of cytoarchitectonic areas and white matter fibre tracts have been created to localize this functionally relevant information in relation to macroanatomical landmarks and to coregister them with activation data from functional neuroimaging (Eickhoff et al. 2005). This is illustrated for activations in the inferior frontal cortex related to imagery of figure-of-eight movements performed with the right index finger (Binkofski et al. 2000). It is shown that the activations overlapped with Brodmann area 44 (Figure 1).

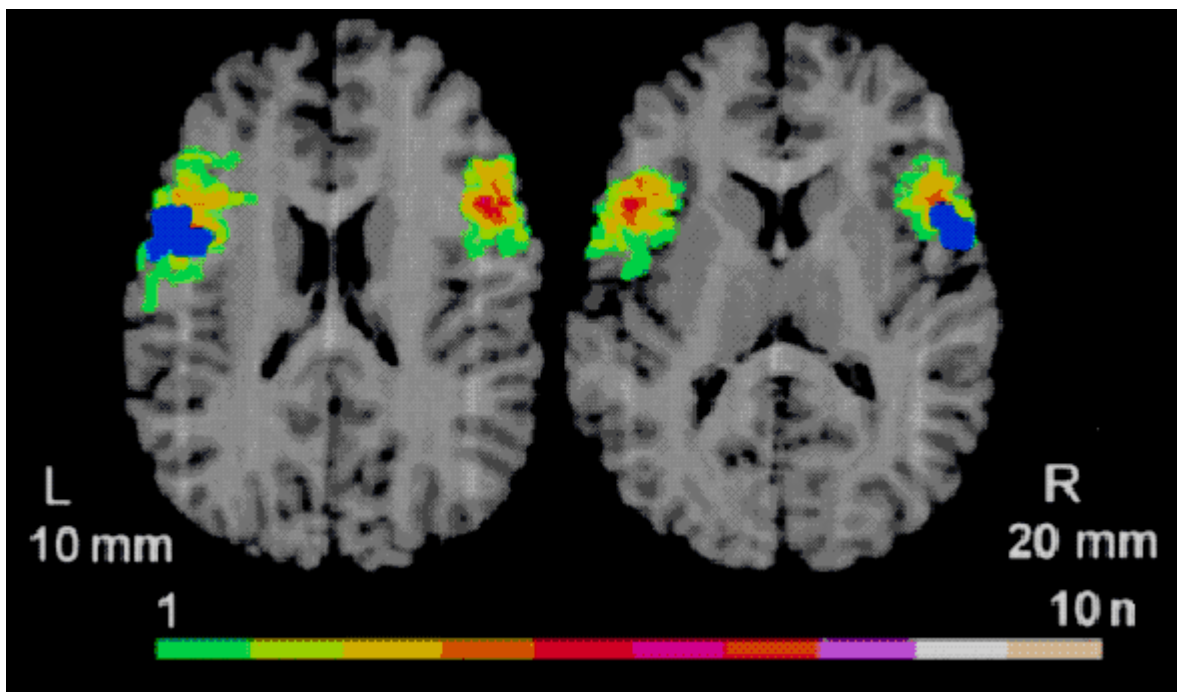


Figure 1: fMRI-activations related to imagery of figure-of-eight movements performed with the right index finger (blue area) in co-registration with probabilistic maps of cytoarchitectonic area 44. The colour coding indicates the spatial overlap of area 44 in ten individual brains. The data have been spatially normalized and superimposed onto structural MR images at 10 mm and 20 mm dorsal to the intercommissural plane, respectively. Further details in Binkofski et al. (2000).

The activations did not extend rostrally into the location of Brodmann area 45 which bears cognitive functions nor caudally into the adjacent Brodmann 6, which belongs to the premotor cortex. Even an inflation of the brain such that sulci appear in continuity with the cerebral gyri on the surface of the brain as well as complete flat maps have been developed for improved cerebral localization of activation areas (Fischl et al. 1999).

4. Processes underlying writing

Handwriting is a voluntary motor act. It is guided by visual feedback as the writing person observes the appearance of the letters and words he/she is writing. It is known that handwriting is performed with fast movements of the arm while the pen is being held virtually motionless in the hand (Kunesch et al. 1989). Handwriting has a high arm movement frequency in contrast to the slow movements in object manipulation with many points of reversal per movement stroke (Kunesch et al. 1989, Marquardt & Mai 1994). Functional neuroimaging studies have endeavoured to explore which brain areas participate in the motor performance of handwriting, guiding writing, in learning of the writing movements, and in the brain areas related to the semantic content of writing. However, due to the difficulty of writing in a lying position in a functional imaging scanner and the gross arm movements during handwriting, which may even result in head movements and, thus, image artefacts, only a limited number of neuroimaging studies of writing have been performed so far. The following is an overview of neuroimaging studies on writing.

In two quite similar PET-studies on fast and slow handwriting with the dominant right hand, foci of activation were found in the left dominant sensorimotor circuitry involving the sensorimotor cortex, the lateral premotor cortex, the left anterior parietal cortex, the left supplementary motor area, the right precuneus, the left putamen, and the right anterior cerebellum (Seitz et al. 1997, Siebner et al. 2001). These areas showed a graded increase in activation related to the number of inversions in velocity per writing stroke (Siebner et al. 2001). Notably, in slow and exact writing of letters the anterior inferior parietal cortex was activated, while in fast writing of letters the posterior parietal cortex became activated (Seitz et al. 1997). This suggested two different modes of sensory guidance engaged in handwriting: focussed object-based guidance for slow movements and large-scale visuospatial guidance for fast movements (Figure 2). This

interpretation was in line with the hypothesis of closed-loop type I and ballistic type II movements (Freund 1986). Moreover, the data reflect the dichotomy of an object-based ventral stream and a dorsal stream for visuospatial information processing (Ungerleider & Haxby 1994). Both the anterior inferior and the posterior superior parietal cortical areas were activated bilaterally when subjects imagined handwriting in comparison to holding a pen motionless on the writing pad (Figure 2). In addition, there was an activation in the right anterior cingulate area which probably was related to subjective valuation of the imagined movement trajectories (Seitz et al. 2009).

Recently, it was shown in an fMRI-study that writing to dictation activated the left sensorimotor cortex, premotor cortex, supplementary motor area, superior parietal lobe, and the dorsal portion of the inferior parietal cortex (Menon & Desmond 2001). In writing Japanese Kanji, subjects were required to combine several parts of a morpheme into the total Kanji symbol. Imaging of Kanji writing was found to be related to a bilateral activation of the premotor cortex, the pre-supplementary motor area and the posterior and inferior parietal lobule next to the occipital lobe (Matsuo et al. 2001). Sugihara et al. (2006) attempted to identify the brain areas specific for handwriting using fMRI, when they compared writing names with silent naming. It was observed that three areas were activated: the posterior end of the left superior frontal gyrus, the anterior part of the left superior parietal lobule and the lower anterior part of the left supramarginal gyrus. Similarly, areas of fMRI activation related to writing the names of pictures and naming pictures silently involved the left superior parietal lobule, bilaterally the posterior and middle portions of the superior frontal cortex, and the right cerebellum (Katanoda et al. 2001). These dorsal stream areas can be related to upper arm movement control (Rizzolatti et al. 1998).

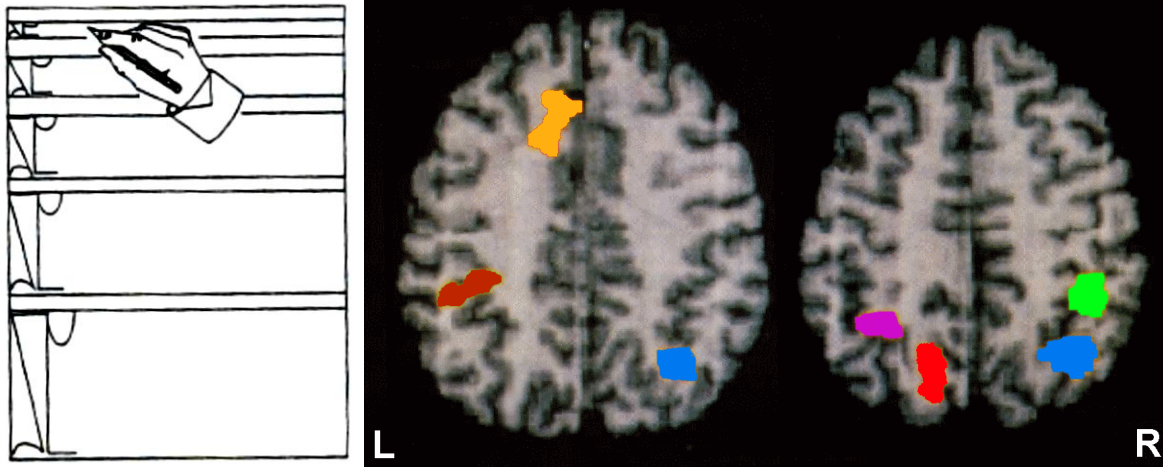


Figure 2: Graphemes bare of semantic content (left side). Activation areas related to imagery of writing graphemes occurred in the left anterior cingulate (yellow) and bilaterally in parietal cortex (right side). The left parietal activations were the same as in learning (brown), after learning (magenta), as well in and after learning of writing graphemes (red). The right parietal activations overlapped with those in learning to write graphemes and in the exact writing of letters (green), and with those in and after learning to write graphemes as well as in the fast writing of letters (blue). Further details in Seitz et al. (1997).

Other studies aimed at singling out the brain areas that mediate visual guidance of writing movements by the particular characteristics of letters and words. These studies were evaluated by Bolger and collaborators (2005) who compiled 25 different studies of Western European, Chinese and Japanese languages. The authors found that the different writing systems engaged largely the same systems in terms of cortical regions. However, localization within these regions suggested differences across the writing systems. Most importantly, there was an area in the left mid-fusiform gyrus which was consistent in localization across writing systems and was called the visual word form area (Bolger et al. 2005). This area corresponded closely to the activation area in the left posterior inferior temporal cortex related to writing Kanji (morphograms) as found in an fMRI-study in 10 healthy native Japanese speakers (Nakamura et al. 2000). This visual word form area most likely belongs to the ventral, occipito-temporal pathway which signifies the “what” contents of writing. Importantly, this area appears to be tuned towards a hierarchy of local combination detectors which allow humans to decipher increasingly larger fragments of words with high sensitivity and speed (Dehaene et al. 2005).

Handwriting is a skill which is usually acquired during the first year of school, subsequently being perfected by repetitive use. In fact, everybody knows that handwriting is quite specific to a person, but the written letters may change in configuration during lifespan related to the amount and speed of writing. Short-term learning to write graphemes was found to modulate activity patterns not only in the parietal cortex but also across cortical and subcortical motor relay structures. An initial activation in the cerebellum was attenuated during the learning process, while conversely the dorsal premotor cortex became more active (Seitz et al. 1994). These findings were in accordance with contemporary theories of motor learning (Willingham 1998). Furthermore, the initial activation of the right inferior parietal cortex resembled a similar activation found in the learning of sequential finger movements (Seitz & Roland 1992b, Seitz et al. 1997, Ungerleider et al. 2002).

Longcamp et al. (2008) performed a learning study using fMRI and compared hand- and typewriting. These authors found that there was a stronger and longer lasting facilitation during several weeks for recognizing the orientation of characters that had been written by hand as compared to those typed. FMRI showed that there was greater activity related to learning of handwriting and normal letter identification in several brain areas which are known to be involved in the execution, imagery and observation of actions. These areas were the sensorimotor cortex, the supplementary motor area, and the anterior and posterior parietal cortex.

Only few studies attempted to identify the brain areas mediating semantic processing during writing. In a PET-study it was found that the posterior inferior temporal gyrus was activated in Kanji writing, which is the writing of complex morphograms, while the left angular gyrus was activated in Kana writing, which is the writing of simple symbols (Tokunaga et al. 1999). While morphograms activated ventral “what” channel areas of information, processing seemingly related to the processing of object-type information, Kana writing activated the left inferior parietal cortex which has been implicated in the analytical processing of lexical information. More recently, it was found using fMRI that hand- and typewriting involve specifically the left inferior frontal cortex, i.e. Broca’s area, and bilaterally the inferior parietal lobule (Longcamp et al. 2008). These activation data confirm earlier findings in relation to the writing and imagery of writing figures (Binkofski et al. 2000). Specifically, Brodmann area 44 was found to be specifically activated when subjects became engaged in generating figure of eight trajectories with their right index finger when compared with being at rest (Figure 1). These activation data

correspond nicely to clinical observations in two example patients with transient cerebral ischemia. Using MRI it was found that written naming was selectively impaired as a result of a hypoperfusion in the left posterior inferior frontal gyrus and precentral gyrus which returned to normal when blood flow was restored (Hillis et al. 2003).

5. Perspectives

Writing for producing a coherent text is a complex process demanding cognitive operations such as conception, planning, working memory, and subjective valuation, in addition to generating dedicated sensorimotor activity. In the centre, there is the acting writer who plans his writing actions, writes the text, and reviews what he has written. First of all, this involves brain activity related to the guidance of sensorimotor activity. Secondly, reviewing the text involves reading and comprehension. For both aspects brain structures are involved as described in this review. Finally, however, the writer may edit the text in order to improve phrasing and sharpen the content. This is a highly differentiated feedback activity requiring the subject to keep his conceptual plan active during the process of sensorimotor integration. In fact, the act of writing takes place in a certain environment in which the writing actor becomes aware of the topic he is going to write about, the potential audience, and his motivation to initiate writing (Hayes & Flower 1980). In a manner of feedback processing of what has been written in comparison to the mental image of what is going to be written, the written text is subsequently updated and revised. This is a multilayered cognitive or mental endeavour involving the writer's intention, working memory, and problem solving strategies. These cognitive processes have been studied using functional neuroimaging, but not in the context of writing.

At a broader level, there is the writer's long term-memory, involving the knowledge of the content of the topic to be written about and the actual discourse knowledge. According to Bereiter & Scardamalia (1987) writing involves the mental construction of the topic and is developed in view of the demand and the knowledge systems of the writer. More recently, it was proposed that a specialized functional and interactive framework may present the basis for the neural system involved in writing and similarly in reading. This highly specialized framework is composed of genetic influences, white matter tract structure, cortical nodes of language

representation, and culturally based organization of writing systems (Schlaggar & McCandliss 2007).

At this point in time, a fair amount is known about the brain structures involved in sensorimotor integration, language representation, working memory and problem solving strategies. Moreover, there is quite some information about the sensorimotor areas engaged in writing and how they are differentially activated during the process of learning handwriting. Also, the site of visual word form recognition has been localized in the human brain. In addition, it was found that the left inferior frontal gyrus and the left inferior parietal cortex are of critical importance for written language production very much in accordance with the big picture of speech processing in the human brain (Indefrey & Levelt 2004). However, virtually nothing is known about which brain areas are critical for constructing a written text, for initiating and maintaining writing, for elaborating the text, and for approving the final version of the text. Here, broad perspectives for future research are on the horizon.

References

- Alexander, G.E.; Moeller, J.R. (1994) Application of the subprofile model to functional imaging in neuropsychiatric disorders: A principal component approach to modeling brain function in disease. *Human Brain Mapping* 2, 79-94.
- Amunts, K.; Schmidt-Passos, F.; Schleicher, A.; Zilles, K. (1997) Postnatal development of interhemispheric asymmetry in the cytoarchitecture of human area 4. *Anatomy Embryology (Berlin)* 196, 393-402.
- Azari, N.P.; Arnold, S.; Schlaug, G.; Niemann, H.; Ebner, A.; Lüders, H.; Witte, O.W.; Seitz, R.J. (1999) Reorganized patterns of metabolic interactions in temporal lobe epilepsy. *Neuropsychologia* 37, 625-636.
- Bandettini, P.A.; Kwong, K.K.; Davis, T.L.; Tootell, R.B.H.; Wong, E.C.; Fox, P.T.; Belliveau, J.W.; Weisskoff, R.M.; Rosen, B.R. (1997) Characterization of cerebral blood oxygenation and flow changes during prolonged brain activation. *Human Brain Mapping* 5, 93-109.
- Beauchamp, M.S.; Haxby, J.V.; Jennings, J.E.; DeYeo, E.A. (1999) An fMRI version of the Farnsworth-Munsell 100Hue test reveals multiple color-sensitive areas in human ventral occipitotemporal cortex. *Cerebral Cortex* 9, 257-263.

- Binkofski, F.; Amunts, K.; Stephan, K.M.; Posse, S.; Schormann, T.; Freund, H.J.; Zilles, K.; Seitz, R.J. (2000) Broca's region subserves imagery of motion: a combined cytoarchitectonic and fMRI study. *Human Brain Mapping* 11, 273-285.
- Bereiter, C.; Scardamalia, M. (1987) *The psychology of written composition*. Lawrence Erlbaum Associates, Hillsdale, NJ, USA.
- Blomqvist, G.; Seitz, R.J.; Sjögren, I.; Halldin, C.; Stone-Elander, S.; Widen, L.; Solin, O.; Haaparanta, M. (1994) Regional cerebral oxidative and total glucose consumption during rest and activation studied with positron emission tomography. *Acta Physiologica Scandinavica* 151, 29-43.
- Bolger, D.J.; Perfetti, C.A.; Schneider, W. (2005) Cross-cultural effect on the brain revisited, universal structures plus writing system variation. *Human Brain Mapping* 25, 92-104
- Broca, P. (1861) Remarques sur le siège de la faculté du langage articulé, suivies d'une observation d'aphémie (perte de la parole). *Bulletin de la Société Anatomique de Paris*, 6, 330-357.
- Büchel, C.; Friston, K.J. (1997) Modulation of connectivity in visual pathways by attention: cortical interactions evaluated with structural equation modelling and fMRI. *Cerebral Cortex* 7, 768-778.
- Buckner, R.L.; Goodman, J.; Burock, M.; Rotte, M.; Koutstaal, W.; Schacter, D.; Rosen, B.; Dale, A.M. (1998) Functional-anatomic correlates of object priming in humans revealed by rapid presentation of event-related fMRI. *Neuron* 20, 285-296.
- Calamante, F.; Thomas, D.L.; Pell, G.S.; Wiersma, J.; Turner, R. (1999) Measuring cerebral blood flow using magnetic resonance imaging techniques. *Journal of Cerebral Blood Flow and Metabolism* 9, 701-735.
- Dehaene, S.; Cohen, L.; Sigman, M.; Vinckier, F. (2005) The neural code for written words, a proposal. *Trends in Cognitive Science* 9, 335-341.
- D'Esposito, M.; Aguirre, G.K.; Zarahn, E.; Ballard, D. (1997) Functional MRI studies of spatial and non-spatial working memory. *Cognitive Brain Research* 7, 1-13.
- Drevets, W.C.; Burton, H.; Videen, T.O.; Snyder, A.Z.; Simpson, J.R. Jr.; Raichle, M.E. (1995) Blood flow changes in human somatosensory cortex during anticipated stimulation. *Nature* 373, 249-252.

- Eickhoff, S.B.; Stephan, K.E.; Mohlberg, H.; Grefkes, C.; Fink, G.R.; Amunts, K.; Zilles, K. (2005) A new SPM toolbox for combining probabilistic cytoarchitectonic maps and functional imaging data. *Neuroimage* 25, 1325-1335.
- Evans, A.C.; Beil, C.; Marrett, S.; Thompson, C.J.; Hakim, A. (1988) Anatomical-functional correlation using an adjustable MRI-based region of interest atlas with positron emission tomography. *Journal of Cerebral Blood Flow and Metabolism* 8, 513-530.
- Fischl, B.; Sereno, M.I.; Dale, A.M. (1999) Cortical surface-based analysis. II: Inflation, flattening, and a surface-based coordinate system. *Neuroimage* 9, 195-207.
- Fox, P.T.; Raichle, M.E. (1984) Stimulus rate dependence of regional cerebral blood flow in human striate cortex, demonstrated by positron emission tomography. *Journal of Neurophysiology* 51, 1109-1120.
- Frackowiak, R.S.J. (1994) Functional mapping of verbal memory and language. *Trends in Neuroscience* 17, 109-115.
- Frahm, J.; Bruhn, H.; Merboldt, K.-D.; Hänicke, W. (1992) Dynamic MR imaging of human brain oxygenation during rest and photic stimulation. *Journal of Magnetic Resonance Imaging* 2, 501-505.
- Freund, H.J. (1986) Time control of hand movements. *Progress in Brain Research* 64, 287-294
- Friston, K.J.; Frith, C.D.; Liddle, P.F.; Frackowiak, R.S.J. (1993) Functional connectivity: the principal-component analysis of large (PET) data sets. *Journal of Cerebral Blood Flow and Metabolism* 13, 5-14.
- Friston, K.J. (1994) Functional and effective connectivity in neuroimaging: a synthesis. *Human Brain Mapping* 2, 56-78.
- Friston, K.J.; Fletcher, P.; Josephs, O.; Holmes, A.; Rugg, M.D.; Turner, R. (1998) Event-related fMRI: Characterizing differential responses. *Neuroimage* 7, 30-40.
- Gur, R.C.; Turetsky, B.; Matsui, M.; Yan, M.; Bilker, W.; Hughett, P.; Gur, R.E. (1999) Sex differences in brain gray and white matter in healthy young adults: correlations with cognitive performance. *Journal of Neuroscience* 15, 4065-4072.
- Hasnain, M.K.; Fox, P.T.; Woldorff, M.G. (1998) Intersubject variability of functional areas in the human visual cortex. *Human Brain Mapping* 6, 301-315

- Hartmann, S.; Missimer, J.H.; Stoeckel, M.C.; Abela, E.; Shah, J.; Seitz, R.J.; Weder, B. (2008) Functional Connectivity in Tactile Object Discrimination – A Principal Component Analysis of an Event Related fMRI-Study. *Public Library of Science, Biology* 3, e3831.
- Hayes, J.R.; Flower, L.S. (1980) Identifying the organization of writing processes. In, Gregg, L.W., Steinberg, E.R. (eds.) *Cognitive Processes in Writing*. Lawrence Erlbaum Associates, Hillsdale, NJ, USA, 3-30.
- Hillis, A.E.; Wityk, R.J.; Barker, P.B.; Caramazza, A. (2003) Neural regions essential for writing verbs. *Nature Neuroscience* 6, 19-20.
- Hoge, R.D.; Atkinson, J.; Gill, B.; Crelier, G.R.; Marrett, S.; Pike, G.B. (1999) Linear coupling between cerebral blood flow and oxygen consumption in activated human cortex. *Proceedings of the National Academy of Sciences USA* 96, 9403-9408.
- Hunton, D.L.; Miezin, F.M.; Buckner, R.L.; van Mier, H.I.; Raichle, M.E.; Petersen, S.E. (1996) An assessment of functional-anatomical variability in neuroimaging studies. *Human Brain Mapping* 4, 122-139.
- Indefrey, P.; Levelt, W.J. (2004) The spatial and temporal signatures of word production components. *Cognition* 92, 101-144.
- Kastrup, A.; Li, T.-Q.; Glover, G.H.; Krüger, G.; Moseley, M.E. (1999) Gender differences in cerebral blood flow and oxygenation response during focal physiological neural activity. *Journal of Cerebral Blood Flow and Metabolism* 19, 1066-1071.
- Kennedy, C.; Des Rosiers, M.H.; Skurada, O.; Shinohara, M.; Reivich, M.; Jehle, W.; Sokoloff, L. (1976) Metabolic mapping of the primary visual system of the monkey by means of the autoradiographic [¹⁴C]deoxyglucose technique. *Proceedings of the National Academy of Sciences USA* 73, 4230-4234.
- Katanoda, K.; Yoshikawa, K.; Sugishita, M. (2001) A functional MRI study on the neural substrates for writing. *Human Brain Mapping* 13, 34-42.
- Kosslyn, S.M.; Alpert, N.M.; Thompson, W.L. (1995) Identifying objects at different levels of hierarchy: a positron emission tomography study. *Human Brain Mapping* 3, 107-132.
- Kunesch, E.; Binkofski, F.; Freund, H.J. (1989) Invariant temporal characteristics of manipulative hand movements. *Experimental Brain Research* 78, 539-546.
- Lindenberg, R.; Fangerau, H.; Seitz, R.J. (2007) “Broca’s area” as a collective term? *Brain Language* 102, 22-29.

- Logothetis, N.K.; Pauls, J.; Augath, M.; Trinath, T.; Oeltermann, A. (2001) Neurophysiological investigation of the basis of the fMRI-signal. *Nature* 412, 150-157.
- Longcamp, M.; Boucard, C.; Gilhodes, J.C.; Anton, J.L.; Roth, M.; Nazarian, B.; Velay, J.L. (2008) Learning through hand- or typewriting influences visual recognition of new graphic shapes, behavioural and functional imaging evidence. *Journal of Cognitive Neuroscience* 20, 802-815.
- Marquardt, C.; Mai, N. (1994) A computational procedure for movement analysis of handwriting. *Journal of Neuroscience Methods* 52, 39-45.
- Matsuo, K.; Kato, C.; Tanaka, S.; Sugio, T.; Matsuzawa, M.; Inui, T.; Moriya, T.; Glover, G.H.; Nakai, T. (2001) *Brain Research Bulletin* 55, 549-554.
- McIntosh, A.R.; Gonzalez-Lima, F. (1994) Structural equation modeling and its application to network analysis in functional brain imaging. *Human Brain Mapping* 2, 23-44.
- McIntosh, A.R.; Grady, C.L.; Ungerleider, L.G.; Haxby, J.V.; Rapoport, S.I.; Horwitz, B. (1994) Network analysis of cortical visual pathways mapped with PET. *Journal of Neuroscience* 14, 655-666.
- Menon, R.S.; Kim, S.-G. (1999) Spatial and temporal limits in cognitive neuroimaging with fMRI. *Trends in Cognitive Science* 3, 207-216.
- Menon, V.; Desmond, J.E. (2001) Left superior parietal cortex involvement in writing, integrating fMRI with lesion evidence. *Cognitive Brain Research* 12, 337-340.
- Mesulam, M.M. (1990) Large-scale neurocognitive networks and distributed processing for attention, language, and memory. *Annals of Neurology* 28, 597-613.
- Nakamura, K.; Honda, M.; Okada, T.; Hanakawa, T.; Toma, K.; Fukuyama, H.; Konishi, J.; Shibasaki, H. (2000) Participation of the left posterior inferior temporal cortex in writing and mental recall of kanji orthography, a functional MRI study. *Brain* 123, 954-967.
- Petersen, S.E.; Fox, P.T.; Posner, M.I.; Mintun, M.; Raichle, M.E. (1988) Positron emission tomographic studies of the cortical anatomy of single-word processing. *Nature* 331, 585-589.
- Price, C.J.; Moore, C.J.; Friston, K.J. (1997) Subtractions, conjunctions, and interactions in experimental design of activation studies. *Human Brain Mapping* 5, 264-272.
- Raichle, M.E. (1987) Circulatory and metabolic correlates of brain function in normal humans. In: Plum, F. (ed.) *Handbook of Physiology. The Nervous System. Volume V: Higher Functions of the brain*. Bethesda, MD: American Physiological Society, 643-674.

- Rizzolatti, G.; Luppino, G.; Matelli, M. (1998) The organization of the cortical motor system: new concepts. *Electroencephalography Clinical Neurophysiology* 106, 283-296.
- Roland, P.E.; Geyer, S.; Amunts, K.; Schormann, T.; Schleicher, A.; Malikovic, A.; Zilles, K. (1997) Cytoarchitectural maps of the human brain in standard anatomical space. *Human Brain Mapping* 5, 222-227.
- Schlaggar, B.L.; McCandliss, B.D. (2007) Development of neural systems for reading. *Annual Reviews of Neuroscience* 30, 475-503.
- Schlaug, G.; Knorr, U.; Seitz, R.J. (1994) Inter-subject variability of cerebral activations in acquiring a motor skill. A study with positron emission tomography. *Experimental Brain Research* 98, 523-534.
- Schlaug, G.; Jäncke, L.; Huang, Y.; Steinmetz, H. (1995) In vivo evidence of structural brain asymmetry in musicians. *Science* 267, 699-701.
- Schormann, T.; Kraemer, M. (2003) Voxel-Guided Morphometry (VGM) and application to stroke. *Institute of Electrical and Electronics Engineers, Transactions in Medical Imaging* 22, 62-74.
- Seitz, R.J.; Bohm, C.; Greitz, T.; Roland, P.E.; Eriksson, L.; Blomkvist, G.; Rosenkvist, G.; Nordell, B. (1990) Accuracy and precision of the computerized brain atlas programme (CBA) for localization and quantification in positron emission tomography. *Journal of Cerebral Blood Flow and Metabolism* 10, 443-457.
- Seitz, R.J.; Roland, P.E. (1992a) Vibratory stimulation increases and decreases the regional cerebral blood flow and oxidative metabolism: a positron emission tomography (PET) study. *Acta Neurologica Scandinavica* 86, 60-67.
- Seitz, R.J.; Roland, P.E. (1992b) Learning of finger movement sequences: a combined kinematic and positron emission tomography study. *European Journal of Neuroscience* 4, 154-165
- Seitz, R.J.; Canavan, A.G.M.; Yagüez, L.; Herzog, H.; Tellmann, L.; Knorr, U.; Huang, Y.; Hömberg, V. (1994) Successive roles of the cerebellum and premotor cortices in trajectorial learning. *Neuroreport* 5, 2541-2544.
- Seitz, R.J.; Canavan, A.G.M.; Yagüez, L.; Herzog, H.; Tellmann, L.; Knorr, U.; Huang, Y.; Hömberg, V. (1997) Representations of graphomotor trajectories in the human parietal cortex, evidence for controlled processing and automatic performance. *European Journal of Neuroscience* 9, 378-389.

- Seitz, R.J.; Franz, M.; Azari, N.P. (2009) Value judgments and self-control of action: The role of the medial frontal cortex. *Brain Research Reviews* 60, 368-378.
- Shulman, G.L.; Fiez, J.A.; Corbetta, M.; Buckner, R.L.; Miezin, F.M.; Raichle, M.E.; Petersen, S.E. (1997) Common blood flow changes across visual tasks. II. Decreases in cerebral cortex. *Journal of Cognitive Neuroscience* 9, 648-663.
- Siebner, H.R.; Limmer, C.; Peinemann, A.; Bartenstein, P.; Drzezga, A.; Conrad, B. (2001) Brain correlates of fast and slow handwriting in humans, a PET-performance correlation analysis. *European Journal of Neuroscience* 14, 726-736.
- Steinmetz, H.; Huang, Y.; Seitz, R.J.; Knorr, U.; Herzog, H.; Hackländer, T.; Kahn, T.; Freund, H.-J. (1992a) Individual integration of positron emission tomography and high-resolution magnetic resonance imaging. *Journal of Cerebral Blood Flow and Metabolism* 12, 919-926.
- Steinmetz, H.; Jäncke, L.; Kleinschmidt, A.; Schlaug, G.; Volkmann, J.; Huang, Y. (1992b) Sex but no hand difference in the isthmus of the corpus callosum. *Neurology* 42, 749-752.
- Sugihara, G.; Kaminaga, T.; Sugishita, M. (2006) Interindividual uniformity and variety of the „Writing center“, a functional MRI study. *Neuroimage* 32, 1837-1849.
- Talairach, J.; Tournoux, P. (1988) Co-planar stereotaxic atlas of the human brain. Thieme, Stuttgart, New York.
- Tokunaga, H.; Nishikawa, T.; Ikejiri, Y.; Nakagawa, Y.; Ysuno, F.; Hashikawa, K.; Nishimura, T.; Sugita, Y.; Takeda, M. (1999) Different neural substrates for Kanji and Kana writing: a PET study. *Neuroreport* 8, 3315-3319.
- Ungerleider, L.G.; Haxby, J.V. (1994) “What” and “where” in the human brain. *Current Opinion in Neurobiology* 4, 157-165.
- Ungerleider, L.G.; Doyon, J.; Karni, A. (2002) Imaging brain plasticity during motor skill learning. *Neurobiology of Learning Memory* 78: 553-564.
- Wernicke, C. (1874) *Der aphasische Symptomencomplex*. Breslau: Cohn & Weigert.
- Willingham, D.B. (1998). A Neuropsychological Theory of Motor Learning. *Psychological Reviews* 105, 558–584.
- Worsley, K.J.; Evans, A.C.; Marrett, S.; Neelin, P. (1992) A three-dimensional statistical analysis for CBF activation studies in human brain. *Journal of Cerebral Blood Flow and Metabolism* 12, 900-918.

Biographical data

Rüdiger Seitz received his approbation as physician and his doctoral degree from the University of Hamburg, Germany, in 1981. After a residency in neuropathology and neurology at the University of Düsseldorf, he was a research fellow at the PET-centre and the Institute of Clinical Neurophysiology at the Karolinska Institute, Stockholm, Sweden, from 1987 until 1989. He achieved the habilitation in neurology at the University of Düsseldorf in 1990. In 1996 he was promoted to Professor of Neurology and became Deputy Head of the Department of Neurology at the University Hospital Düsseldorf in 1998. In 2006-2007 he was Distinguished Fellow at the Institute of Advanced Study at La Trobe University and the National Stroke Research Institute in Melbourne, Australia.